

Vascular lab report
Assessed by: Emily Blake (CVS)

| | | | | | |
|--------|------------|----------------|------------|----------------|------------|
| Name | [REDACTED] | Hospital | [REDACTED] | Date of Exams: | 14/03/2019 |
| DOB: | [REDACTED] | NHS No | [REDACTED] | Ip/Op: | OP |
| Referr | [REDACTED] | Hospital Site: | UHL | | |

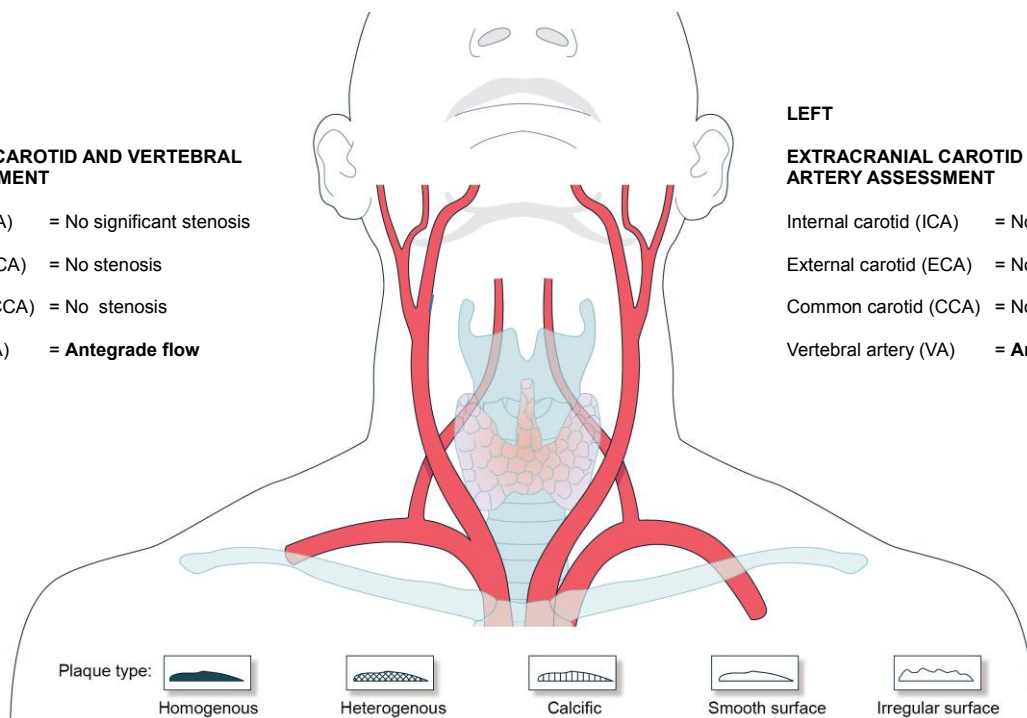
Clinical Indications: old stroke to rule out carotid disease (or vertebral)

Carotid and Vertebral Artery – Duplex scan
RIGHT
EXTRACRANIAL CAROTID AND VERTEBRAL ARTERY ASSESSMENT

Internal carotid (ICA) = No significant stenosis
 External carotid (ECA) = No stenosis
 Common carotid (CCA) = No stenosis
 Vertebral artery (VA) = **Antegrade flow**

LEFT
EXTRACRANIAL CAROTID AND VERTEBRAL ARTERY ASSESSMENT

Internal carotid (ICA) = No stenosis
 External carotid (ECA) = No stenosis
 Common carotid (CCA) = No stenosis
 Vertebral artery (VA) = **Antegrade flow**


Report:
RIGHT:

The Common (CCA), Internal (ICA) and External (ECA) carotid arteries are patent with no significant stenosis detected. Minimal amount of echogenic atheroma noted within the bulb.

ICA Peak Systolic Velocity (PSV) = 0.65m/sec

ICA End Diastolic Velocity (EDV) = 0.25m/sec.

The Vertebral artery is patent with antegrade blood flow detected.

LEFT: Tortuous ICA noted.

The Common (CCA), Internal (ICA) and External (ECA) carotid arteries are patent with no stenosis detected.

ICA Peak Systolic Velocity (PSV) = 0.83m/sec.

ICA End Diastolic Velocity (EDV) = 0.30m/sec.

The Vertebral artery is patent with antegrade blood flow detected.

Conclusion:

Patent carotid arteries with no haemodynamically significant stenosis detected bilaterally.
Antegrade vertebral flow.